



# **Cataract Theatre Skills**

## **Module 8 Complications**

# Welcome to Complications



- ◉ Warren Howell
- ◉ Trainer & Sales in Ophthalmology for 20 Years
- ◉ Please ask questions!
- ◉ Email [warren@medsalesacademy.co.uk](mailto:warren@medsalesacademy.co.uk)



# Today we will learn

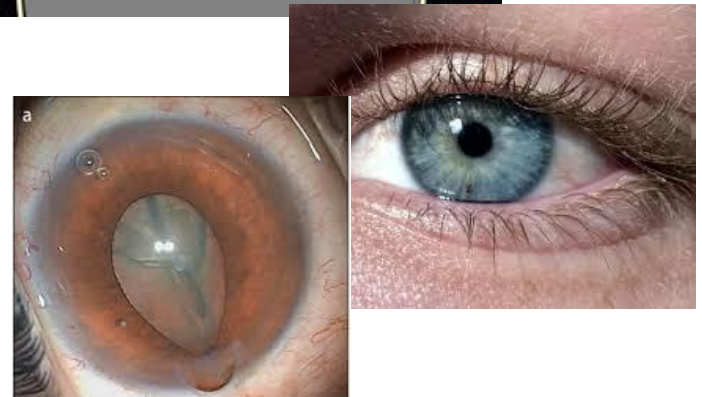
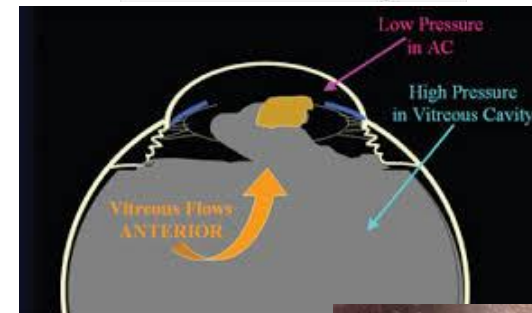
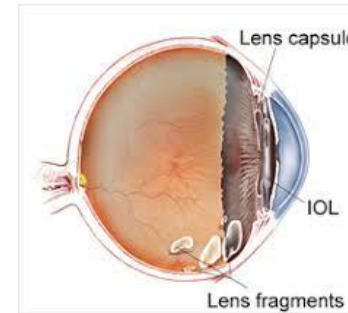


- ◉ Capsular Bag Ruptures
- ◉ Vitreous in Anterior Chamber
- ◉ Sulcus Fixated IOL
- ◉ Dropped Nucleus
- ◉ Floppy Iris Syndrome
- ◉ Mature Cataract making imaging tricky

# Possible Complications of Cataract Surgery



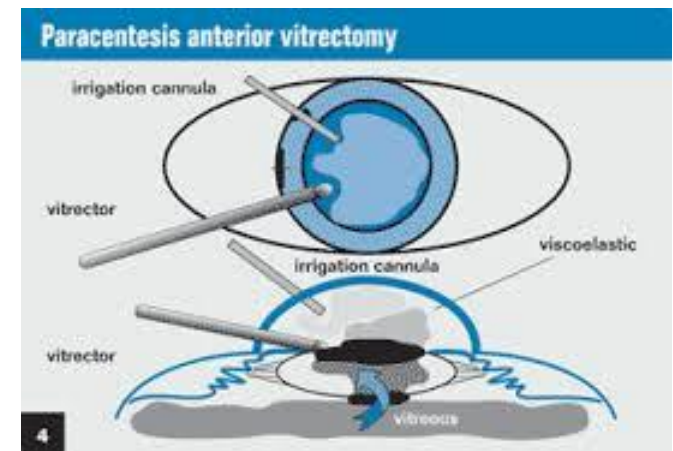
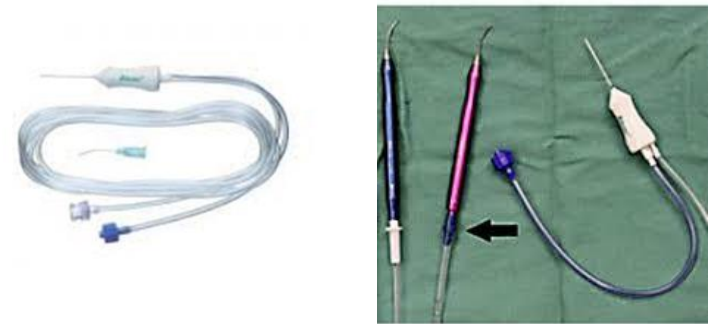
- Capsular Bag Ruptures resulting in the Nucleus Dropping into the Vitreous Cavity
- Capsular Bag Rupture resulting in vitreous entering the Anterior Chamber
- Floppy Iris Syndrome or Iris fails to dilate
- Mature Cataract making the visualisation of the capsule difficult for creating a capsulorhexis
- Capsular bag is damaged or fragile



# Anterior Vitrectomy for resolution of vitreous loss



- If the capsular bag during Phaco surgery ruptures, the surgeon may need to carry out an Anterior Vitrectomy
- The Anterior Vitrectomy procedure is designed to remove any vitreous strands that have prolapsed into the anterior chamber
- The Anterior Cutter is designed in a way, so as to minimise traction on the vitreous humour
- The scrub team should ALWAYS have a sterile in date Anterior Vitrectomy pack in the Cataract Theatre
- There should also be a stock of anterior vitrectomy packs in the Prep Room

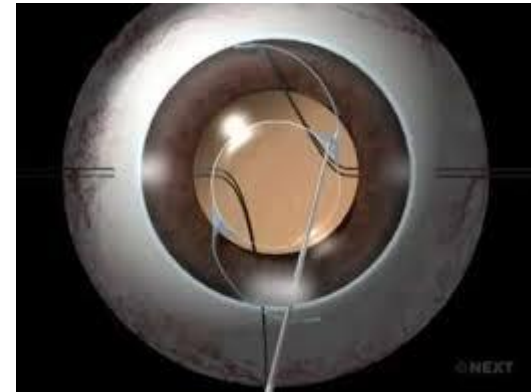


# Sulcus Fixated IOL

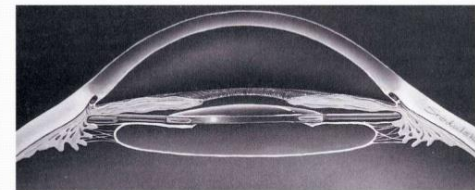


## Sulcus IOL Procedure

- If the capsular bag is compromised or unstable
- If the posterior capsule has a defect
- If the Zonules are loose or compromised
- The Scrub team should always have a Sulcus Fixated IOL available (Size will be as per the Biometry Printout)



## Ciliary sulcus fixation

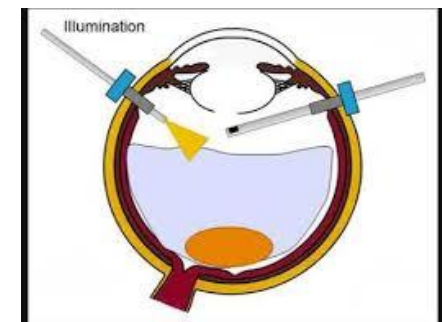
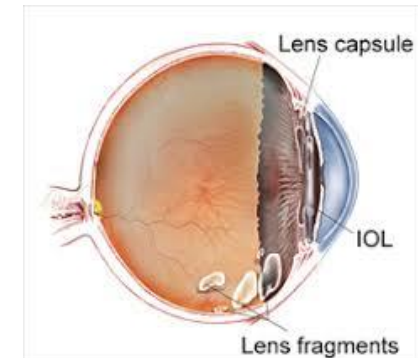


# Dropped Nucleus

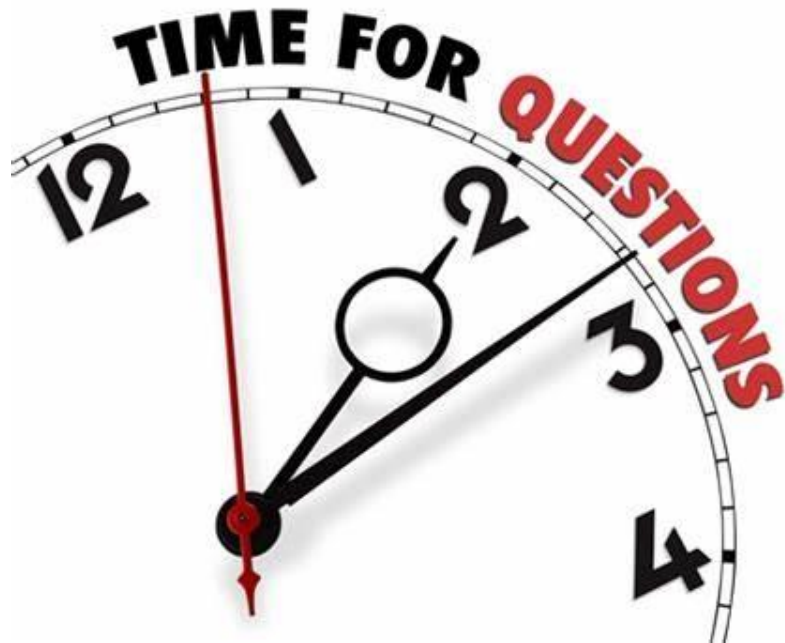

## Dropped Nucleus Procedure

- All surgeons at some point may encounter a situation where the capsular bag tears and the remaining nucleus segments drop into the vitreous
- Although this is an emergency situation, it is imperative that the surgeon & scrub team remain calm - 90% of Phaco patients will be conscious
- All instruments will be removed from the eye
- If required an Anterior Vitrectomy can be carried out to 'clean up' the anterior chamber
- All incisions should be sealed & Pupil management is also carried out
- Immediate referral to the Vitreoretinal team



# Question Time





# Floppy or Difficult to Dilate Iris



- Some cataract surgery patients will have a Floppy Iris Syndrome
- Other patients may have issues with the ability of the pupil to dilate
- There are surgical products that can help to stabilize and expand the iris
- Iris Hooks have been in use since the 1990s
- Newer devices have been developed Pupil Expander devices EG APX – Malyugin Ring

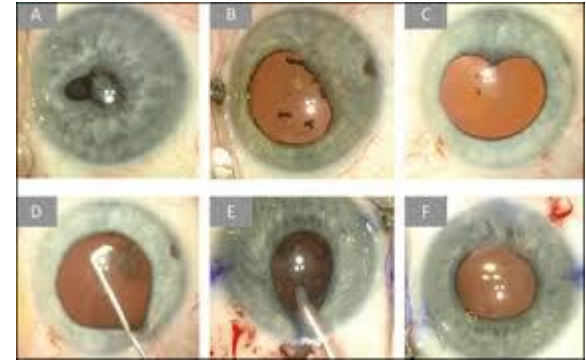
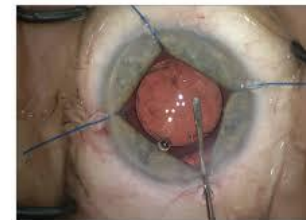
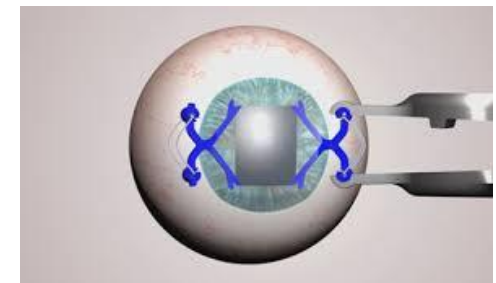


Figure 4: Iris hooks being used to enlarge the pupil



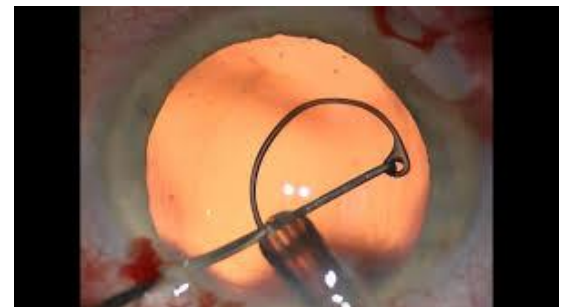
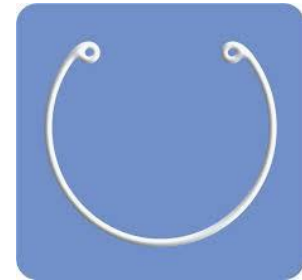Iris hooks can be used to enlarge the pupil beyond 7 mm, which can help control intraoperative floppy iris syndrome. Placing one or two hooks subconjunctivally can improve access through the wound.



# Unstable or Damaged Capsular Bag (Zonules)



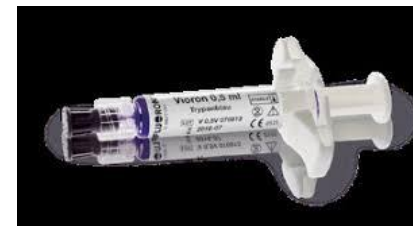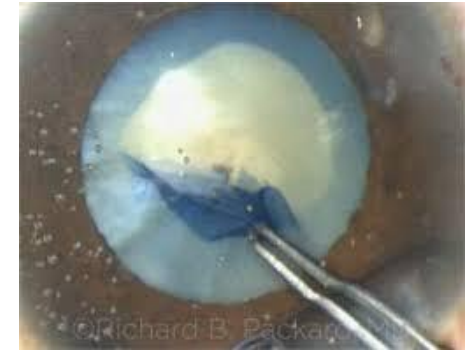- If the surgeon is concerned about the viability of the capsular bag for Phaco surgery
- Or the capsular bag is compromised (tear) or the Zonules are weak
- A capsular tensioning device can be used to strengthen the capsular bag
- This should guard against capsular bag ruptures resulting in an Anterior Vitrectomy or Dropped Nucleus
- Most capsular tension rings now are sold in a pre-loaded injector



# Mature Cataract and Visualization of the Capsule



- If the surgeon is concerned about inadequate visualization of the capsular bag
- Trypan Blue Dye can be used to stain the capsular membrane blue
- This should aid the surgeon to perform the capsulorhexis



# Question Time



# Today we have learnt



- ◉ Capsular Bag Ruptures
- ◉ Vitreous in Anterior Chamber
- ◉ Sulcus Fixated IOL
- ◉ Dropped Nucleus
- ◉ Floppy Iris Syndrome
- ◉ Mature Cataract making imaging tricky

# Thank-you



- ◉ We hope this course was useful
- ◉ We are happy to take your questions
- ◉ [warren@medsalesacademy.co.uk](mailto:warren@medsalesacademy.co.uk)
- ◉ We hope to see you soon on another course

# MSA Courses



- ◉ Biometry
- ◉ Topography
- ◉ Ultrasound
- ◉ Visual Fields
- ◉ OCT
- ◉ Cataract Theatre Skills
- ◉ VR Theatre Skills
- ◉ Intraocular Surgery with Prof Tom Williamson
- ◉ Vitreoretinal Disorders in Primary Care with Prof Tom Williamson
- ◉ Vitreoretinal Surgery with Prof Tom Williamson

# Congratulations

